


PATIENT CARE / EDUCATION / RESEARCH / COMMUNITY SERVICE

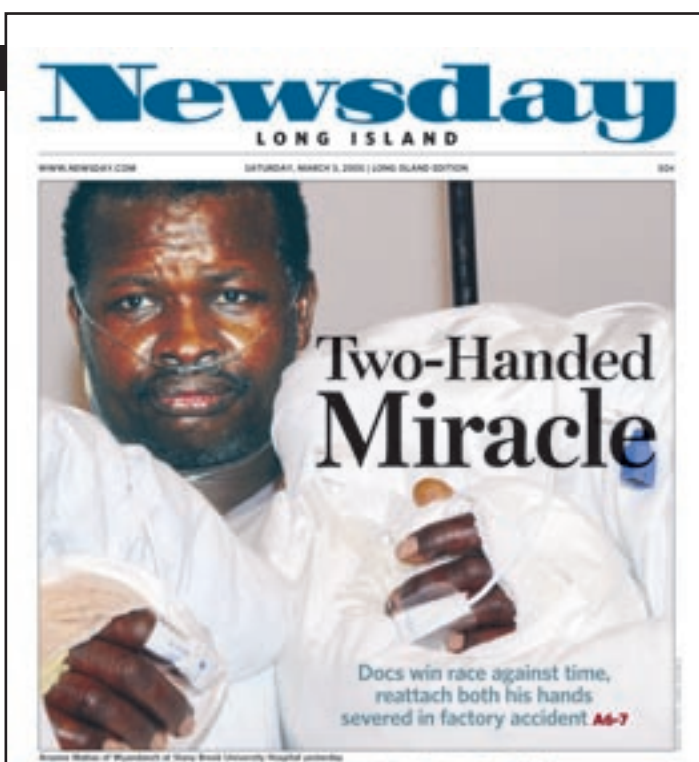NEWS UPDATE FROM THE
DEPARTMENT OF SURGERY
UNIVERSITY HOSPITAL AND
HEALTH SCIENCES CENTER
AT STONY BROOK
APRIL 2005

POST-OP



Performing a Medical Miracle With Multidisciplinary Surgery

*Making Surgical History
And National News*



Beating the clock was a major factor in the happy outcome of this dramatic multidisciplinary operation that took about 11 hours to complete. A detached hand, if placed in an ice-slurry, has just 12 hours before it can no longer be successfully reattached, according to Dr. Dagum.

Our surgeons performed what is believed to be the first simultaneous reattachment of hands done in New York State.


Stony Brook University Hospital is one of just two replantation centers in the downstate region of New York and the only one on Long Island, where surgeons have the ability—the necessary expertise in reconstructive microsurgery—to reattach severed limbs. Our seemingly miraculous ability in this area of emergency care is among the many reasons why Stony Brook is the designated Level I Trauma Center serving our region.

The clock started ticking at around 9 o'clock in the morning on the last day of February, as soon as Arsenio Matias had a terrible accident at his factory job in Bay Shore, NY. At the moment he looked down to see blood gushing from his wrists and both of his hands lying on the floor beside the machine he had been operating, the 49-year-old man thought he was going to die.

But thanks to the first-aid of his coworkers and, ultimately, to the state-of-the art care of the physicians at Stony Brook University Hospital, he didn't die. Not only that—as if a miracle—his hands were successfully reattached in a history-making operation led by Alexander B. Dagum, MD, associate professor of surgery and chief of plastic and reconstructive surgery.

Finger amputations are a common injury but complete hand amputations are rare. Stony Brook surgeons perform a multitude of finger reattachments every year in contrast to one single-hand reattachment operation about every one to two years.

The simultaneous reattachment of both hands is so rare that, previous to the present case, Dr. Dagum had known of only one other such operation, which took place in China.



Saving This Man's Life Through Teamwork

It started out as an ordinary Monday. Mr. Matias was doing his job at a display-making factory, operating a vacuum form machine that has parts to help form plastic and then cut it to size. But suddenly his hands got caught in the machine and severed at the wrists—all in a split second.

Soon after the accident took place, one coworker put him in a chair and told him to raise his arms over his head to slow the bleeding. Two other coworkers tied their belts around his arms to further stem the bleeding. Other workers there ran to a nearby store to get ice to store his hands in. The phone call to 911 brought to the scene the Suffolk County Police helicopter that quickly airlifted him to University Hospital, about 18 miles away.



The grateful and happy patient, Arsenio Matias (seated) with surgeon Dr. Alexander Dagum. Standing behind them are anesthesiologists Dr. Kenneth Rosenfeld (left) and Dr. Neera Tewari.

JOHN GRIFFIN | MEDIA SERVICES | STONY BROOK UNIVERSITY

Mr. Matias entered our emergency room just over an hour after the accident took place. At that point, he had lost almost 40% of his blood, nine pints in all. Our trauma team—led by Marc J. Shapiro, MD, professor of surgery and anesthesiology, and chief of general surgery, trauma, surgical critical care, and burns—successfully stabilized the patient whose injuries were nothing less than devastating.

At around 10:30 a.m. Kenneth I. Rosenfeld, MD, associate professor of anesthesiology and vice chairman for clinical affairs, brought the patient who was still awake to the

operating room. Another anesthesiologist, John A. Petrie, MD, assistant professor of anesthesiology, came to help with the preparations needed to ready the patient for surgery. Together, they placed intravenous and monitoring lines and further stabilized him.

Dr. Dagum soon arrived to start the operation. He immediately went to work to control the bleeding and then commenced preparing the parts of the patient's hands and arms.

"This was one of the greatest challenges of my career," says Dr. Dagum, who has been doing replantations for 12 years.

Dr. Dagum, the lead surgeon of the operation, was then joined by three other hand surgery specialists: Balvant P. Arora, MD, assistant professor of surgery (plastic and reconstructive surgery); Lawrence C. Hurst, MD, professor and chairman of orthopaedic surgery and chief of hand surgery; and Steven P. Sampson, MD, associate

professor and associate chairman of orthopaedic surgery.

Dr. Dagum worked closely together with Dr. Arora. They focused their attention on the patient's left hand, while Drs. Hurst and Sampson worked together on the right hand. Neera Tewari, MD, assistant professor of anesthesiology, arrived to take over for Dr. Petrie in the management of the anesthesia. Three orthopaedic surgery residents provided assistance during the case.

Late in the operation, another hand surgery specialist, Edward D. Wang, MD, assistant professor of orthopaedic surgery, came to help briefly by relieving Dr. Hurst, who had been working steadily for many hours.

By the ninth hour of the replantation procedure involving complex reconstructive microsurgery, the patient's reattached hands began to take on their normal color, and the outcome of the surgery became clear to the team in the operating room.

Life had been restored to the two hands that earlier in the day were dead. The operation was at last a success—and the patient a lucky man.

The Operation Itself

The 11-hour operation that was performed to reattach Arsenio Matias' hands involved a team of four surgeons working simultaneously, with two on each hand:

[Hours 0-2]

PREPARING FOR SURGERY

The patient was hemorrhaging from both arms, and so the bleeding vessels were isolated and microsurgical clamps applied to stop the bleeding. The severed hands, which had been put in an ice-slurry to preserve them, were then cleaned of any dead tissue, as were the arms at the point of the injury. Clamps and sutures were used to identify all bones, tendons, blood vessels, and nerves to be reconnected.

[Hours 2-3]

MATCHING UP THE PARTS

Hand and arm bones were then rejoined with pins—and set to grow together. Clamps were removed, and sutures tied to reconnect a total of 24 tendons in each hand.

Performing Reconstructive Microsurgery

Our clinical program in reconstructive microsurgery offers truly state-of-the-art care for some of the most clinically vexing problems that, until recently, were virtually unsolvable.

Microsurgery involves magnifying the visual field of surgeons to enable them to see better, dissect better, and perform micro-manipulation. This magnification helps them to perform very precise surgery that was not possible in the past.

The greatest impact of microsurgery has been in our ability to suture small blood vessels and nerves, thus making it possible to replant—reattach—limbs severed from the body, as well as to transplant tissues from one part of the body to another.

Microsurgical techniques greatly enhance the reconstructive surgeon's armamentarium for dealing with a multitude of complex reconstructive problems. By reestablishing blood flow into and out of muscle tissue, skin, bone, or even a portion of small intestine, the plastic surgeon so trained is able to perform seemingly miraculous operations—like the operation in which the severed hands of Arsenio Matias were successfully reattached.

All four of our plastic surgeons—as well as otolaryngologist-head and neck surgeons on our faculty—have expertise in reconstructive microsurgery, for which they completed advanced training, and their skills enable them to perform all kinds of new operations that seem miraculous.

Microsurgery first drew clinical attention in the late 1960s and early 1970s when it was used mainly as a tool to assist with the reattachment of severed fingers and limbs. The dissecting microscope provided a means of visualizing and repairing injured small blood vessels and nerves. Its use in general reconstructive surgery soon followed.

Plastic surgeons learned that they could sever the blood vessels supplying a chosen donor tissue, and transfer it to a “distant” site where it was needed to solve a reconstructive problem. This new modality rendered many previous multi-stage procedures obsolete, and in many instances provided reconstructive options where none before existed.

Although a relatively new form of surgery, reconstructive microsurgery is now widely accepted. Over the last three decades more than 100 donor “flaps”—pieces of tissue completely severed from their place of origin that are transplanted to a new site to reconstruct a tumor defect—have been described, and a nationwide success rate of over 90% has been realized.

NEW POSSIBILITIES FOR THERAPY

Reconstructive microsurgery offers a wide range of therapeutic possibilities. Injuries to limbs that previously could only be treated by amputation can now be successfully treated and the limbs reconstructed with functional results.

Cancers resulting in the loss of the cervical portion of the esophagus can now be reconstructed with transplantation of a portion of the patient's own small intestine. Even reconstruction of the breast can be enhanced via microsurgical techniques.

Lost digits can be reconstructed with toe-to-hand transfers, even years after their loss. And burn reconstruction can be made more functional and aesthetically appealing.

The increasing application of microsurgical techniques is currently being seen more and more in limb preservation surgery for trauma, tumor resection, congenital abnormality, and organ transplant.

All told, the advent of microsurgery has been one of the most important developments in modern surgery, and it has made possible rapid, major advances in the field of plastic and reconstructive surgery.

[Hours 3-9]

MAKING DELICATE REPAIRS & RESTORING BLOOD FLOW

Two major arteries, four veins with two vein grafts, and two major nerves in each hand were repaired. Circulation was reestablished, with the cold, pale hands turning warm and pink—indicating the success of the operation. Some sutures were so fine, as the thickness of a hair, that the surgeons used microscopes and magnifying glasses, performing what is called *reconstructive microsurgery*.

[Hours 9-11]

CLOSING UP

The right forearm skin and connective tissue had to be cut to release pressure from the traumatized forearm. Skin grafts were then applied to the right hand, and finally the skin was sutured in the hands.

During the course of the long operation, nearly 100 other hospital staff members provided the surgeons with the support they needed in- and outside the operating room.



(left to right) Dr. Lawrence Hurst, surgeon; Dr. Neera Tewari, anesthesiologist; Dr. Alexander Dagum, lead surgeon; Dr. Kenneth Rosenfeld, anesthesiologist; Dr. Steven Sampson, surgeon; and Dr. Balvant Arora, surgeon—at news conference held at Stony Brook on March 4.

Our program in reconstructive microsurgery offers patients the most sophisticated care available for

- Reattachment of acutely severed body parts
- Soft-tissue trauma of the arms/hands and legs/feet
- Reconstruction after limb-sparing tumor removal
- Cancers involving the head and neck, including the cervical esophagus, mandible and floor of the mouth
- Severe burn scar contracture of the neck and shoulders
- Traumatic or congenital absence of digits, especially the thumb
- Breast reconstruction
- Limb salvage in patients with peripheral vascular disease
- Management of difficult wounds
- Vascular and vasospastic disorders of the hand, such as Raynaud's syndrome
- Nerve injuries in the arms/hands and legs/feet

Our colleagues in the Department of Orthopaedics—Stony Brook Orthopaedics Associates, PC—also perform reconstructive microsurgery for replantation of severed fingers and limbs, as well as for other kinds of operations.

overleaf:

Dr. Alexander Dagum (left) describing the operation, with anesthesiologist Dr. Kenneth Rosenfeld and surgeon Dr. Steven Sampson.



JOHN GRIFFIN | MEDIA SERVICES | STONY BROOK UNIVERSITY

MAKING NEWS WITH A MEDICAL MIRACLE

At the news conference held at Stony Brook University Hospital four days after the successful operation, where reporters and camera crews of local and national news media had gathered to cover this miraculous story, Dr. Dagum said about the operation, “To take something that literally is dead, and all of a sudden, to see life in it again is very gratifying.”

Mr. Matias himself, his arms wrapped in surgical dressing as thick as pillows, was at the news conference, and in response to the question about how he was feeling, he just smiled and said, “Perfect, perfect—I never have pain. This is unbelievable.” And then, about the surgeons who took care of him, he said, “These doctors are the best in the world.”

In late March, almost four weeks to the day of his accident, Mr. Matias was able to leave the hospital and go home. Soon after he started his physical therapy. He faces about a year of rehabilitation, including exercises to regain strength in his hands and increase his range of motion. According to Dr. Dagum, he should regain 50% of the motion of his hands and 50% of the feeling. Although that prognosis may sound limiting, the outcome is still great, considering how much damage had been done in the accident.

All of us at University Hospital are proud of the historic success of our surgeons. This success reflects the amazing ability of their surgical expertise and their multidisciplinary teamwork.

But more than that, it also represents the success of nearly 100 other hospital staff members who provided them with the support they needed in- and out-side the operating room, as well as the success of the county’s rescue team and the quick-thinking coworkers who, together, helped us beat the clock to save one man—one very grateful man today.



Stony Brook Surgical Associates, PC

BREAST CARE

John S. Brebbia, MD
Martyn W. Burk, MD, PhD
Louis T. Merriam, MD
Brian J. O'Hea, MD

BURN CARE

John S. Brebbia, MD
Marc J. Shapiro, MD
Harry S. Soroff, MD

CARDIOTHORACIC SURGERY

Thomas V. Bilfinger, MD, ScD
Irvin B. Krukenkamp, MD
Allison J. McLarty, MD
Frank C. Seifert, MD

GENERAL/GASTROINTESTINAL SURGERY

John S. Brebbia, MD
Martyn W. Burk, MD, PhD
Marvin L. Corman, MD
Martin S. Karpeh, Jr., MD
Louis T. Merriam, MD
David E. Rivadeneira, MD
Marc J. Shapiro, MD
James A. Vosswinkel, MD
Kevin T. Watkins, MD

OTOLARYNGOLOGY-HEAD AND NECK SURGERY (ENT)

Prajoy P. Kadvade, MD
Arnold E. Katz, MD
Denise C. Monte, MD
Ghassan J. Samara, MD
Maisie L. Shindo, MD

PEDIATRIC SURGERY

Thomas K. Lee, MD
Cedric J. Priebe, Jr., MD
Richard J. Scriven, MD

PLASTIC AND RECONSTRUCTIVE SURGERY

Balvant P. Arora, MD
Duc T. Bui, MD
Alexander B. Dagum, MD
Steven M. Katz, MD

SURGICAL ONCOLOGY

John S. Brebbia, MD
Martyn W. Burk, MD, PhD
Marvin L. Corman, MD
Martin S. Karpeh, Jr., MD
Louis T. Merriam, MD
Brian J. O'Hea, MD
David E. Rivadeneira, MD
William B. Smithy, MD

TRANSPLANTATION

John J. Ricotta, MD
Wayne C. Waltzer, MD

TRAUMA/SURGICAL CRITICAL CARE

John S. Brebbia, MD
Marc J. Shapiro, MD
James A. Vosswinkel, MD

VASCULAR SURGERY

Enrique Criado, MD
Antonios P. Gasparis, MD
Cheng H. Lo, MD
John J. Ricotta, MD

For consultations/appointments with our physicians, please call
(631) **444-4550** for our specialists in breast care
(631) **444-2565** for our specialists in burn care
(631) **444-1820** for our specialists in cardiothoracic surgery
(631) **444-4545** for our specialists in general/gastrointestinal surgery
(631) **444-4121** for our specialists in otolaryngology-head and neck surgery (ENT)
(631) **444-4545** for our specialists in pediatric surgery
(631) **444-9287** for our specialists in plastic and reconstructive surgery
(631) **444-2565** for our specialists in surgical oncology
(631) **444-2209** for our specialists in transplantation
(631) **444-2565** for our specialists in trauma/surgical critical care
(631) **444-2565** for our specialists in vascular surgery
(631) **723-5000** for our specialists at Stony Brook Outpatient Services in Hampton Bays: pediatric surgery

Please visit the **Department of Surgery** website at www.uhmc.sunysb.edu/surgery

The State University of New York at Stony Brook is an equal opportunity/affirmative action educator and employer. This publication can be made available in an alternative format upon request.

OFFICE LOCATIONS

University Hospital

Level 5, Suite 6
Nicolls Road
Stony Brook, NY 11794
631-444-2565 tel
631-444-8973 fax

Surgical Care Center

37 Research Way
East Setauket, NY 11733
631-444-4545 tel
631-444-4539 fax

POST-OP is published by the
Department of Surgery
University Hospital and
Health Sciences Center
Stony Brook University
Stony Brook, New York

Editor-in-Chief

John J. Ricotta, MD

Writer/Editor

Jonathan Cohen, PhD

Contributing Editor

Andrew E. Toga, FACHE

Advisory Board

Enrique Criado, MD
Alexander B. Dagum, MD
Martin S. Karpeh, Jr., MD
Arnold E. Katz, MD
Irvin B. Krukenkamp, MD
Margaret A. McNurlan, PhD
Cedric J. Priebe, Jr., MD
Marc J. Shapiro, MD

All correspondence
should be sent to:

Dr. Jonathan Cohen
Writer/Editor, POST-OP
Department of Surgery
Health Sciences Center T19
Stony Brook, NY 11794-8191
USA

Cover Photo Credit

Daniel Goodrich.
© 2005, Newsday.
Distributed by
Tribune Media Services.
Reprinted with permission.